

GnRH Vaccination in Elephants

Dr. Imke Lueders, GEOLIFES, Hamburg (imke.lueders@geolifes.com),

Dr. Ann-Kathrin Oerke, European Elephant Service, Goettingen (akoerke@dpz.eu)

This summary is based on existing publications, personal experience of the authors with the GnRH vaccines in female Asian elephants as well as own research projects on male Asian and African elephants.

What is a GnRH vaccine?

The GnRH vaccine is a prepared inoculant designed to induce an immune response against the endogenous hormone GnRH. GnRH stands for “Gonadotropin Releasing Hormone” which is secreted by the hypothalamus. The GnRH is the beginning of a hormonal chain reaction, the hypothalamic-pituitary-gonadal-axis (Fig. 1). In fact, the secretion of GnRH triggers the release of further hormones, the gonadotrophins Luteinizing Hormone (LH) and Follicle Stimulating Hormone (FSH) from the pituitary gland. As their common name suggests, these hormones act on the gonads (testicles, ovaries) and up-regulate their function. In females, this is the growth, maturation (FSH) and ovulation (LH) of follicles and the subsequent secretion of estrogens and progesterone. In males, the gonadotrophins are responsible for the development of sperm (FSH) and the secretion of testosterone (LH).

Comparable to a “flu shot”, the GnRH vaccine triggers anti-body production by introducing a stranger protein to the body’s immune system. In response to the injection of the protein-conjugated, exogenous GnRH, antibodies will neutralize GnRH produced naturally in the body (Fig. 2). By binding onto the body’s own GnRH, the antibodies prevent the GnRH from taking its action, because now it is unable to bind to its receptors in the pituitary (= hypophysis, Fig. 2). Subsequently, no LH or FSH is released anymore and the testicles or ovaries will not be stimulated and become inactive.

Thus, the GnRH vaccine is not an administered external hormone, but stops the endogenous GnRH action by stimulation of an immune response against its own hormone. Originally, the GnRH vaccine was developed for male piglets and cattle, due to welfare issues arising against surgical castration (Bonneau and Enright, 1995, Dunshea et al., 2001). It has since been used in a variety of animals to control fertility.

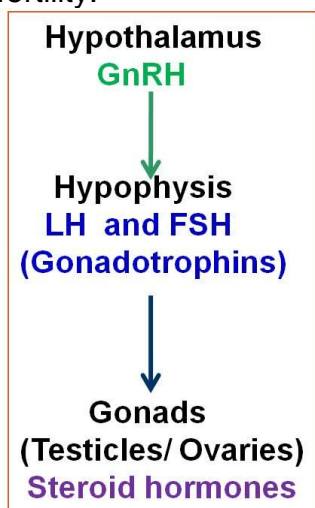


Fig. 1 hypothalamic- pituitary -gonadal -axis

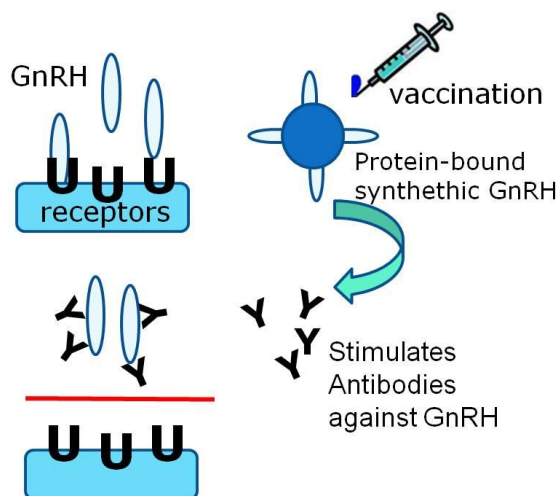


Fig. 2 Schematic of the GnRH vaccine action

Available GnRH vaccines

The company Zoetis (formerly Pfizer Animal Health) began marketing several commercially available GnRH vaccines recently. It started with a horse formulation for suppression of estrus in performance mares in Australia, but soon it got licensed for the meat production industry and made its big appearance in pig and cattle breeding. Table 1 gives an overview of available products.

Table 1 Examples of different GnRH vaccines available today

Brand Name	Target species	Conc.	Company	Used in elephants
EquiTy	Horse	200 µg/ml	Zoetis	yes
Improvac	Pig	150µg/ml	Zoetis	yes
Improvest	Pig	200µg/ml	Zoetis	yes
Bopriva	Cattle	400µg/ml	Zoetis	yes
GonaCon	Feral/pest animals	?	USDA, USA	no
ReproBloc	Domestic, non food animals	?	Amplicon Vaccine LLC, USA	yes
GnRH vaccine	Pig	500 µg/ml	Pepscan, NL	yes

GnRH vaccination in elephants

Lately, GnRH has been suggested as a non-surgical method to control testosterone levels and musth in bull elephants or to prevent uterine pathologies in females (Stout et al., 2007). However, very little is known about the dosages, vaccination intervals, long-term and side effects of this drug in elephants. The total number of studied elephants comprises of 12 captive Asian elephant bulls (Rajapaska et al., 2010; Lueders et al., 2014; Somgrid et al., 2015) and 19 captive and 4 wild African elephant males (De Nys et al., 2010; Bertschinger & Sills, 2013; Lueders et al., 2013; Doughty et al., 2014). Only 7 Asian elephant females (Boedeker et al., 2012, 2013) and a group of 8 wild African elephant females (Benavides Valades et al., 2012) are mentioned in studies on GnRH vaccine use in female elephants. Although all of these studies give valuable input on the topic, they mainly focus on hormone secretion, and for males, on testosterone related behaviour. We will add the results for a total of 13 captive and 4 wild African elephants bulls soon, including our findings on the effect of sperm production and ultrasonographic changes in reproductive organs (Lueders et al, in prep). The few published studies that exist, suggest clear differences between the effectiveness in male and female elephants in respect to vaccination intervals and effectiveness. For example, appears testosterone suppressed after primer and booster injection in males (Lueders et al., 2013) for at least 5 months, whereas in female African elephants this injection regime did not result in full suppression of estrus cycles (Benavides Valades et al., 2012).

Current knowledge Male elephants

Captive, adult male Asian and African elephants have been monitored in terms of testosterone levels and behaviour (De Nys et al., 2010, Rajapaska et al., 2010, Lueders et al., 2013; Somgird et al., 2015). In general, all authors found a

suppression of testosterone levels and/or suppression of musth in most elephants after two to three injections. Behaviour was modified in certain individuals, which appeared calmer and more attentive to their handlers. Only one subadult Asian elephant male was treated and monitored for testosterone, behaviour, body condition, reproductive organ changes and sperm production (Lueders et al., 2014). This male, who was 7 years at beginning of the study, was treated for 6 years and showed no testosterone production, small testicles, general cessation of reproductive organ growth with underdeveloped penis and no sexual interest or aggression. This male is kept in a group of hands-on females and behaves well. He did not gain as much weight as another male of his age, but his height growth was not altered. He looks more feminine now, resembling a female Asian elephant with tusks.

Antibody titers were shown to rise after 2-3 injections in adult Asian elephant males (Somgrid et al., 2015). However, they remained elevated for only 2 months. Monthly boosters were therefore given in several studies at least at the beginning of the treatment (Rajapsaka et al., 2010; Lueders et al., 2014, Somgrid et al., 2015). In a study with monthly injections for three consecutive months, testosterone levels were back to initial levels about 5 months after the last injection. Similar, in African elephant bulls with 4 injections in 3-7 week intervals, testosterone was back to normal or bulls entered musth 6 months after the last booster (De Nys et al., 2010). In general, longer treatment will cause longer reversal time or even permanent infertility. In the case of the young male in the study of Lueders et al., (2014), the last treatment occurred more than 4 years ago and this bull remained at baseline testosterone levels and appears castrate-like (person comm., Feb. 2016, Charlie Gray, African Lion Safari, Canada).

Correspondingly, evidence out of our test on African elephants over a 3 year course suggests permanent damage, especially in younger individuals (Lueders et al, 2013; Lueders et al., in prep.).

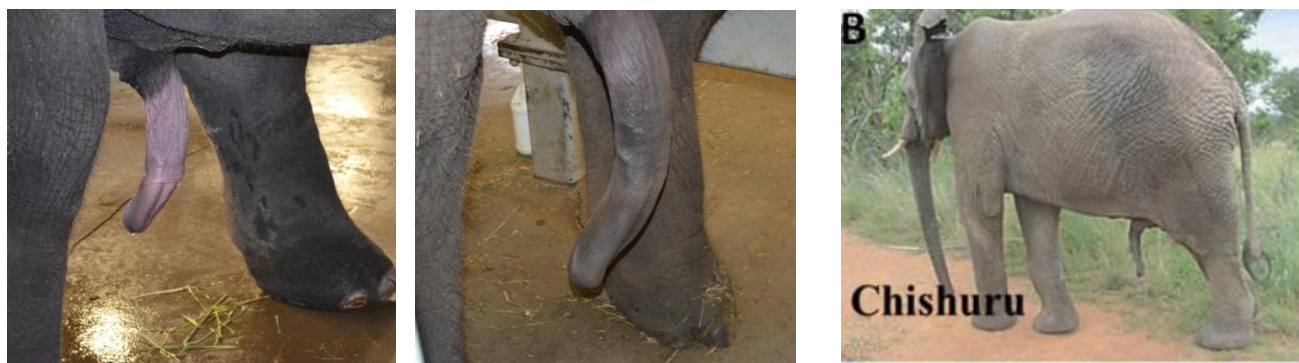

Fig.3 Penis size of treated Asian elephant bull (left) suggest inability to breed compared to similar aged half brother without GnRH vaccine and normal penis development (right). From Lueders et al., 2014; B: image provided by Prof. Henk Bertschinger of a 16 -year old African elephant bull with noticeable penis atrophy treated with GnRH for three years (Bertschinger and Sills (2013).

Current knowledge Female elephants

For female elephants, even less data on the effects of GnRH vaccination are available. The main reasons may be that in a captive situation, females are desperately needed for breeding and there appears no need to treat older, post-reproductive females with a contraceptive. In southern Africa, however, where

contraception is warranted to reduce fecundity, a different, female immuno-contraceptive is already widely applied and highly successful. The pZP-vaccine prevents fertilization of oocytes, while estrous cyclicity remains (Delsink et al., 2002; 2006).

In aged Asian elephant females suppression of ovarian function may be indicated because they are known to develop uterine leiomyoma, especially when they do not reproduce (Montali et al., 1997; Hermes et al., 2004). These tumors of the smooth muscle layer of the uterus (myometrium) are benign and do not pose problems in many cases, but their growth is stimulated by ovarian hormones. Nulliparous, cyclic females >40 years are at increased risk that these tumors break through the mucosal inner layer (endometrium) of the uterine lumen and cause bloody discharge and subsequent uterine infection. Extreme growth of the tumors can also cause pain and obstruction of pelvic organs. We recently were involved in a case of a 50+ years individual bearing a uterus destroyed by a leiomyoma which weighted 375 kg at necropsy (person. communication Hanspeter Steinmetz, 25.Juni 2015).

Studies are currently underway in the U.S. to look at the use of GnRH vaccines to stop or even regress leiomyoma growth and to prevent these problems in post-reproductive females (Boedeker et al., 2012; Boedeker et al, 2013). First results are promising, as induction of anestrus and regression of tumors appears successful (Boedeker et al., 2012, 2013). However, in comparison to some studies in male elephants, it seems that for the suppression of ovarian function, more frequent vaccination intervals and higher doses of GnRH are necessary (Boedeker et al., 2012, person. comm. Janine Brown, March 2016, Fig. 4). This is supported by the results of other authors on wild African elephant females (Benavides Valades et al., 2012). Here, the vaccination schedule of two injections with 600 µg GnRH conjugate (Improvac®) given 5-7 weeks apart resulted in incomplete effectiveness with no complete anestrus (Valades et al., 2012). Dr. Janine Brown reported that they now always use doses of 1000 µg GnRH conjugate in females.

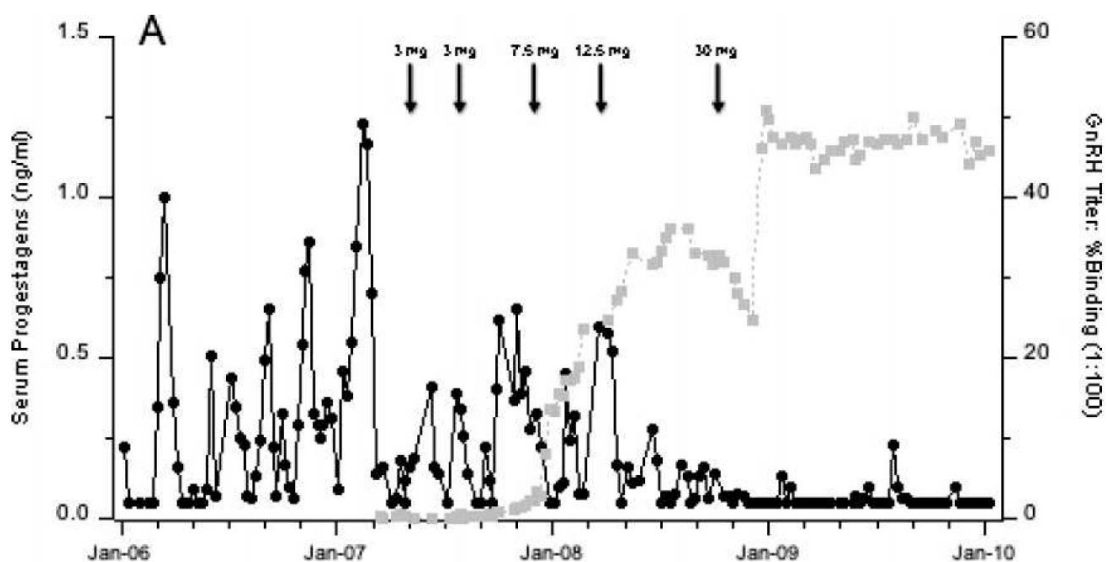


Fig. 4 Profile of serum progesterone (black) and GnRH antibody titers (grey) in relation to vaccination (arrows) of different GnRH conjugate concentrations (Repro-Bloc®), from the publication of Boedeker et al., 2012 on a female Asian elephant treated with GnRH vaccine. Note that titers rose only after increased dose and at least 3 injections!

Recognized Problems associated with the GnRH vaccination

General

In general long term studies are missing for both, male and female elephants. In addition there are no studies on pathologies caused by GnRH vaccinations. From other species it is known for example, that the injection causes acute inflammatory reactions with swelling and pain and we noticed this occasionally in elephants (Fig. 5A). We also saw limping after vaccination into the hind leg for one day in one elephant bull. Abscesses are possible as after any injection, but we have not heard about any case in elephants as of yet. However, a female Indian rhino treated with the vaccine developed a large abscess (pers. comm. Dr. Christine Geiger, Nov. 2015). In the long term, granulomas can be found in the musculature at injection site (e.g. deer, Curtis et al., 2008) which is due to the adjuvant used in these vaccines. Some elephants are reported to feel generally ill up to two days after vaccination with reduced food intake and signs of discomfort (pers. comm. Dr. Tobias Knauf-Witzens, Jan. 2016). A rise in body temperature has been recorded in other species such as cattle (Theubet et al., 2010).



Fig 5. A. Male African elephant showing large swelling at injection site one day after re-vaccination. B. To our knowledge the longest so far treated African elephant bull: He received 6 monthly boosters over the past 13 years (30 years old when photographed, 3.36 cm high, managed in full contact).

Males

Since the GnRH vaccine was not designed to be reversible in the first place, another problem is that it is not known exactly from which point it will produce permanent infertility. Reversibility is already questionable in young males after 2 injections since severe testicular degeneration was reported in other species (deer, sheep: Janett et al., 2003, Curtis et al., 2008). Our studies indicate severe degeneration of testicles (size reduction by up to 60%, amorphous shape, dilated blood vessels and fibrosis) and penis atrophy in male elephants treated for more than 3 years (Lueders et al., 2013; Lueders et al., 2014; Lueders et al, in prep., Fig 3).

Long-term effects (elephants treated for more than 10 years) on the elephants health are also not known. We are aware of one bull in South Africa being on the vaccine for the past 13 years (Fig. 5B). He seems to show no problems related to the vaccination so far. However, in elephant bulls there seems to be a difference in the individual reaction: non-responders are reported in both, Asian elephant (Rajapsaka et al.,

2010, Somgrid et al., 2015) and African elephant bulls (De Nys et al., 2010). Since the effectiveness of a vaccination is always dependent on the immune response, this might explain the individual effects. We have also recognized one African elephant bull in our study that did respond much less than all other males studied, although he was treated in the same manner (Lueders et al., in prep). In the same study on wild and captive African elephant bulls, we noticed a change in hierarchy/rank/dominance. This has been also noted in a study on one wild African bull treated with Improvac® (Doughty et al., 2014). In the latter study, 8 monthly intervals with 3ml of Improvac® were not sufficient to suppress musth, so that the dose needed to be increased to 6ml every 5 months. In conclusion, monitoring of the success of the vaccine by hormone measurement and ultrasound are always important.

Females

Another potential risk has been detected for female elephants: The vaccine is often recommended when clinical signs in form of discharge from the vestibulum occur. This discharge can be mucus, blood, tissue pieces (when parts of the leiomyoma become necrotic) or pus (Fig 6).



Fig. 6 Not uncommon: aged Asian elephant females start discharging blood from the vestibulum when leiomyoma have grown large enough. This may be related to the follicular phase of the estrus cycle. Vaccination should be rather started prior to any discharge, to avoid uterine infection!

All these symptoms, especially in older cows (>40 years) are likely a result of uterine leiomyoma. Investigations as to what the source of discharge is are always recommended! One reason for discharge in old females is that the myometrial tumors broke through the endometrial barrier into the uterine lumen. Continuous discharge of any material presents a great risk of bacterial infection. On top, continuous blood loss can cause anemia. Before GnRH vaccines were available commercially, experiments were undertaken with GnRH agonists to suppress estrus cycles. In a case report by Aupperle et al. (2008), a female was treated with Deslorelin implants to induce acyclicity, reduce tumor growth and prevent further bleeding. While this treatment appeared successful (no ovarian activity and no discharge were noticed anymore after implanted), the elephant died a year later with an enormous pyometra and 250 litres of accumulated pus inside the uterus (Aupperle et al, 2008). With this example in mind, it must be considered that any possible remaining uterine content (mucus, pus, necrotic tissue etc.) may not be discarded anymore once estrus cycles cease and the cervix remains closed. Closure of the cervix due to the interruption of ovarian activity and thus stopping the natural “clearance mechanism of the uterus” should be considered in elephants with any form of discharge prior to treatment with GnRH vaccines. Regular cycle monitoring, ultrasound check up, an intense course of antibiotics and monitoring of leucocyte count are very important. We encountered two worrying cases in this respect: in a 50+ year old female, the GnRH vaccination was

not performed, as uncontrollable infection and massive tumor growth were suspected. This Asian elephant passed necrotic tumorous tissue at the size of a soccer ball three months after ultrasound diagnosis during a new follicular phase. If this necrotic tissue would not have been passed, it may have caused further problems. In another case, GnRH vaccine treatment was started, the female developed abdominal edema, weight loss, and pussy discharge. The vaccination was stopped and the animal treated first with several courses of antibiotics. Only after ultrasound examination and strict regular blood analysis the GnRH vaccine treatment appeared save to continue. These examples are to show that any GnRH vaccination needs proper evaluation of the female prior to start of vaccination in order to avoid animals to be harmed. At the same time, it should be considered to start vaccination before leiomyoma cause these problems.

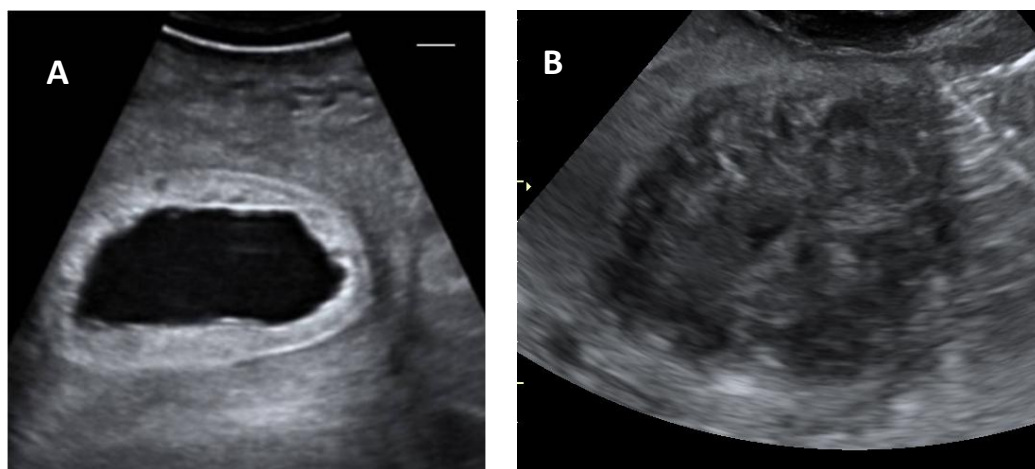


Fig. 7 Examples for pathological uterine findings during ultrasound in female Asian elephants: A. Pyometra: fluid content in uterine horn (black) and inflamed endometrium (white) → vaccination would be detrimental! This condition needs treatment before GnRH vaccination may be considered; B. Leiomyoma in uterine horn destroyed normal appearance at this stage, no distinction of myometrium and endometrium possible anymore → GnRH vaccination may prevent further growth and damage.

Advice for the use of GnRH vaccination in captive elephants based on current knowledge

	Action	Comment
EEP approval	Always inform EEP coordinator/ vet advisors about vaccination plans & receive approval	The vaccine should NEVER be administered to future breeding animals!
Health check/ Blood collection	Hematology, Blood chemistry, body condition, overall health	Prior to vaccination, the elephant should undergo a health screening, immunocompromised elephants will not respond properly to the vaccine!
Hormone monitoring	Female: Measuring of progesterone in serum or its metabolites in urine/feces to check for estrus cycles Male: check testosterone levels	Females: Progestagens 6 months prior to vaccination and at least six months after first injection. Males: Testosterone for 3 months prior to vaccination and at least 6 months after. Continuous monitoring is advised!
Ultrasonography	Prior to vaccination, 6 months after and then at least yearly	Reproductive organ size and pathologies need to be recorded, any abnormalities (e.g. fluid accumulation in the uterus) can be picked up in time, elephants with bloody or pussy discharge have a high risk of uterine infection and development of serious pyometra
Dosage administered	600-1000µg	Dose depends on animal status and age and formulation used, as they may have different concentrations per ml in different products (Table 1)
Route of administration	Deep intramuscular	Long needle is essential to avoid subcutaneous deposition, for hand injection the best region is into neck muscle, by dart in the gluteal region
Injection Interval	Females: 1 st Booster 4 weeks after primer injection, then every months for at least 3 months, then every 4 months, after 1 year, every 6 months, then maybe spaced out to yearly injections. Males: may respond to a lower regime: 1 st Booster 4 weeks after primer injection, then booster every 5 months	There are differences reported in the response, females need higher doses and shorter treatment intervals apparently, antibody titer rises after second or third injection only. So at the beginning, short intervals should be chosen which may be extended later on, after hormone or antibody titer measurement confirmed effectiveness.
Side –Effects (may occur, but not necessarily!)	1. Local reaction (Heat/Swelling) at injection side 2. Lameness 3. Elephant feeling not well 4. Femininisation 5. Behavioural changes	1. Resolves within 10 days 2. Resolves within 1-2 days 3. Seen for up to 2 days with elevated temperature. 4. Males look less masculine 5. Dominant animals may become more quiet, lose their status
Reversibility	Unknown!	Studies on adult male elephants suggest reversibility possible when only 2 or 3 injections were given, any longer treatment or treatment of prepubertal animals may cause permanent damage!

Summary

- An immunocontraceptive – no hormone based contraception!
- Commercially available. Usually in the form of Improvac ©, produced for pigs, but used already in several other (wildlife) species.
- Cheap to buy and easily administered by IM injection
- Can be administered by qualified veterinarian using syringe or dart
- No oral effectiveness, if product or treated animal is ingested
- Important to administer deeply intramuscular, or can cause swellings
- Booster required 4-6 weeks after first injection, regular doses required at 1-6 months intervals thereafter, depending on individual, sex, age etc.
- Antibody titers rise after 2-3 injections of at least 600µg GnRH conjugate and remain elevated for a minimum of two months.
- Booster intervals may be required in 1-2 months intervals at the beginning and may be spaced out over time
- Tested primarily as measure to reduce/reverse pathological changes (leiomyoma) in aged Asian elephant females or as an immuno-castration method in bulls .- proven effects on fertility (sperm quality; testes size and shape, etc.) after third injection
- Has been used successfully to suppress aggressive behaviour and musth in bull Asian and African elephants (see attached publications)
- Testosterone levels usually reduced drastically after two injections
- Changes in behaviour noticeable in most (but not all) bulls. Most bulls are reportedly more relaxed, less aggressive, more attentive to their handlers. Changes in destructive behaviour, such as breaking fences have also been noted.
- It must be emphasized that some bulls do not display these behavioural changes in the same manner due to learned behaviours and personal life histories. Downplay of aggressive tendencies is the trend, but is not guaranteed!
- Can cause changes in dominance hierarchies within groups of both, males and females. If the dominant bull is vaccinated, a younger or less dominant bull has been seen to change behaviour and try to dominate, causing further behavioural changes in other animals within the group. Behavioural changes in females may become apparent as well and may cause (or solve...) conflicts and changes of hierarchial order in existing groups.
- Reversibility is not necessarily possible and depends on duration of vaccination, sex and age as well as on individual properties of the elephant.
- In most species, no effect on pregnancy or lactation is expected, however these effects are unknown in elephants and thus treatment of pregnant/lactating elephants is not recommended!
- CAUTION: do not self-inject, the vaccine is harmful to humans and may cause fertility problems in any species!

Literature (elephant GnRH vaccine related articles marked in bolt)

Aupperle, H., Reinschauer, A., Bach, F., Hildebrandt, T.B., Goeritz, F., Jäger, K., Scheller, R., Klaue, H.-J., and Schoon, H.-A (2008). Chronic endometritis in an Asian elephant (*Elephas maximus*). *J. Zoo. Wildl. Med.* **39**: 107-110.

Benavides Valades, G.B., A. Ganswindt, H. Annandale, M. L. Schulman, and H. J. Bertschinger. 2012. Non-invasive assessment of the reproductive cycle in free-ranging female African elephants (*Loxodonta africana*) treated with a gonadotropin-releasing hormone (GnRH) vaccine for inducing anoestrus. *BMC Reprod. Biol. Endocrinol.* **10:63. (8 free-roaming African elephant females, SA)**

Bertschinger H.J. and Sills E.S. (2013) Contraceptive applications of GnRH-analogs and vaccines for wildlife mammals of southern Africa: current experience and challenges. In: *Gonadotropin-Releasing Hormone (GnRH). Production, Structure and Function*. Scot Sills (Ed), Nova Science Publications Inc, New York 2013.

Boedeker, N.C., L.-A. C. Hayek, S. Murray, D. M.de Avila, and J. L. Brown. (2012). Effect of a gonadotropin-releasing hormone vaccine on ovarian cyclicity and uterine morphology of an Asian elephant (*Elephas maximus*). *J. Zoo Wildl. Med.* **43: 603-614. (1 adult Asian elephant female, USA)**

Boedeker N., Schmitt D, Brown J. (2013) GnRH Vaccination as a Treatment for Reproductive Tract Pathologies in Female Elephants (Contraception for Post-Reproductive Cows? Why Close the Door After the Cow is Out?). *Proceedings of the International Elephant and Rhino Conservation and Research Symposium, Pittsburgh, USA, Sept. 2013.* (7 adult female Asian elephants, captive, USA)

Bonneau, M., & Enright, W. J. (1995). Immunocastration in cattle and pigs. *Livestock Production Science*, *42*(2): 193-200.

Curtis, P. D., Richmond, M. E., Miller, L. A., & Quimby, F. W. (2008). Physiological effects of gonadotropin-releasing hormone immunocontraception on white-tailed deer. *Human-Wildlife Interactions*, 68

Delsink, A. K., Van Altena, J. J., Kirkpatrick, J., Grobler, D., & Fayrer-Hosken, R. A. (2001). Field applications of immunocontraception in African elephants (*Loxodonta africana*). *Reproduction (Cambridge, England) Supplement*, *60*, 117-124.

Delsink, A. K., Van Altena, J. J., Grobler, D., Bertschinger, H., Kirkpatrick, J., & Slotow, R. (2006). Regulation of a small, discrete African elephant population through immunocontraception in the Makalali Conservancy, Limpopo, South Africa. *South African Journal of Science*, *102*(9), 403-408.

De Nys, H.M., H.J. Bertschinger, J.A. Turkstra, D. Colenbrander, R. Palme, and A.M. Human. (2010). Vaccination against GnRH may suppress aggressive behaviour and musth in African elephant (*Loxodonta africana*) bulls – a pilot study. *J. S. African Vet. Ass.* **81: 8–15 (1 free, 5 captive African bulls, South Africa)**

Doughty, L. S., Slater, K., Zitzer, H., Avent, T., & Thompson, S. (2014). The impact of male contraception on dominance hierarchy and herd association patterns of African elephants (*Loxodonta africana*) in a fenced game reserve. *Global Ecology and Conservation*, *2*, 88-96. (1 free roaming African elephant bull, South Africa)

Dunsha, F.R., C. Colantoni, K. Howard, I. McCauley, P. Jackson, K.A. Long, S. Lopaticki, E.A. Nugent, J.A. Simons, J. Walker, and D.P. Hennessyn. (2001). Vaccination of boars with a GnRH vaccine (Improvac) eliminates boar taint and increases growth performance. *J. Anim. Sci.* *79*:2524-2535.

Hermes R, Hildebrandt TB, and Goritz F. (2004). Reproductive problems directly attributable to long-term captivity – asymmetric reproductive aging. *Anim. Reprod. Sci.* *82-83*:49-60.

Janett F., Lanker U., Jörg H., Hässig M., Thun R. (2003) Die Kastration männlicher Lämmer mittels Immunisierung gegen GnRH. *Schweiz. Arch. Tierheilk*, 145: 291-299.

Lueders, I., Hildebrandt, T. B., Gray, C., Botha, S., Rich, P., & Niemuller, C. (2014). Suppression of testicular function in a male Asian elephant (*E. maximus*) treated with Gonadotropin-Releasing vaccines. *Journal of Zoo and Wildlife Medicine*, 45(3), 611-619. (1 subadult Asian, Canada)

Lueders I, Young D, Botha S, Gray C, Luther I, Maree L, van der Horst G, Bertschinger HJ (2013). Suppression of testicular function by means of a GnRH vaccine in African elephant bulls. Proceedings of the International Elephant and rhino Conservation and Research Symposium, Pittsburgh, USA, Sept. 2013 (2 wild, 11 captive African elephants, South Africa)

Lueders I, Young D, Maree L, van der Horst G, Luther I, Botha S, Tindall B, Ganswindt A., Bertschinger H (in prep.). Effects of GnRH vaccination on reproductive organs and spermatogenesis in wild and captive African elephant bulls (*Loxodonta africana*). Manuscript in preparation (4 wild, 13 captive African elephant bulls, SA)

Montali R.J., Th. Hildebrandt, F. Göritz, R. Hermès, R. Ippen and E. Ramsay (1997) Ultrasonography and pathology of genital tract leiomyomas in captive Asian elephants: Implications for reproductive soundness. *Verh.ber. Erkrq.Zootiere* (1997) 38.

Rajapaska, R.C., I.P.G.H.U. Dissanayaka, C.Somgird, C. Thitaram, A. Sirimalaisuwan, P.G.A. Pushpakumara, B. Colenbrander, J.L. Brown, B.M.A.O. Perera, and T.A.E. Stout. (2010). Efficacy of GnRH vaccination for suppressing musth and aggressive behavior in male Asian elephants. EU-Asia Link Project Symposium "Managing the Health and Reproduction of Elephant Populations in Asia" May 2010. Faculty of Veterinary Medicine, University Chiang Mai, Thailand. Pp. 114 -116. (6 captive Asian elephant males, Sri Lanka)

Somgird, C., Homkong, P., Sripiboon, S., Brown, J. L., Stout, T. A., Colenbrander, B., Mahasawangkul, S. & Thitaram, C. (2015). Potential of a gonadotropin-releasing hormone vaccine to suppress musth in captive male Asian elephants (*Elephas maximus*). *Animal Reproduction Science*. (5 captive Asian elephant males, Thailand)

Stout, T. A. E., Bertschinger, H. J., & Colenbrander, B. (2007). The use of GnRH vaccines for reproductive suppression in horses and elephants. In *Proceedings of the EU-Asia Project Symposium "Managing the health and reproduction of elephant populations in Asia": 8-10 October 2007; Bangkok* (pp. 115-119).

Theubet, Thun, Hilbe, & Janett. (2010). Wirkung einer Impfung gegen GnRH (Bopriva®) beim männlichen pubertären Kalb. *Schweizer Archiv für Tierheilkunde*, 152(10), 459-469.